

APPROACH TO A CHILD WITH GASTROINTESTINAL BLEEDING

Definitions

- *haemetemesis* - vomiting out blood whether fresh or stale
- *malaena* - passing out tarry black stools per rectum

Both are medical emergencies that carry significant mortality

Salient features

- duration and severity of haemetemesis and/or malaena
- evidence of hypovolaemic shock
- rule out bleeding diathesis

Figure 1. Acute resuscitation in a child with gastrointestinal bleeding

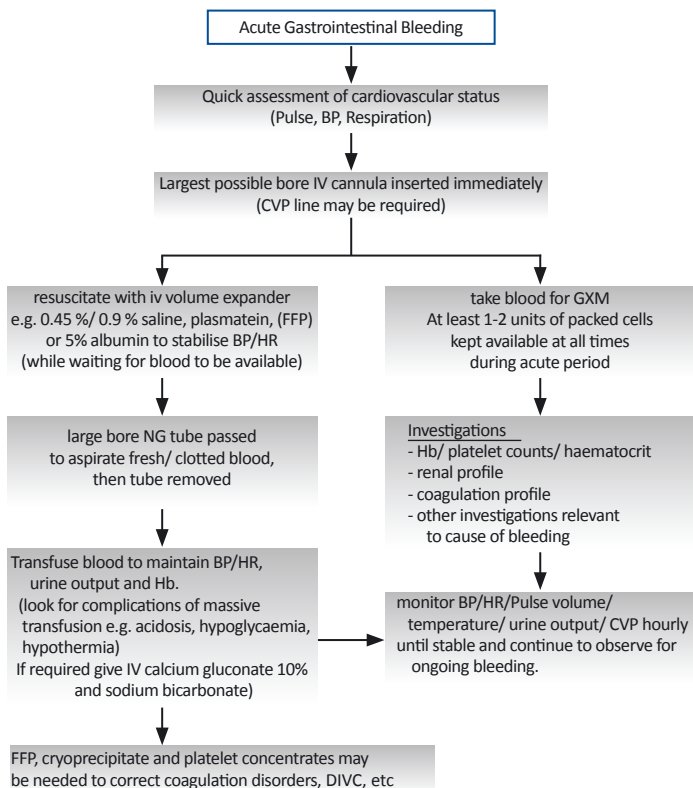


Table 1. Decision making after acute resuscitation

Reassessment of patients	Diagnostic measures to localise source of bleeding
<ul style="list-style-type: none"> When patient's condition is stable and resuscitative measures have been instituted, <i>assess patient for</i> <ul style="list-style-type: none"> cause of bleeding need for surgery <i>History is reviewed.</i> Ask for history of chronic liver disease, dyspepsia, chronic or intermittent gastrointestinal bleeding (e.g. polyps), drug ingestion (anticoagulants, aspirin), or acute fever (dengue haemorrhagic fever), easy bleeding tendencies, etc. <i>Physical exam</i> should be directed towards looking for signs of chronic liver disease (spider angiomas, palmar erythema, portal hypertension or splenomegaly) or telangiectasia / angiomas in mouth, trunk, etc.) 	<ul style="list-style-type: none"> <i>Oesophago-gastro-duodenoscopy (OGDS) or colonoscopy</i> can be performed when patient's condition is stable. <i>Double contrast barium study</i> less useful than endoscopy but may be indicated in patients when endoscopy cannot precisely locate the source of bleeding (e.g. in intussusception) <i>Visceral angiography</i> can precisely locate the source of bleeding. But is only reserved for patients with a difficult bleeding problem.

Table 2. Definitive measures to management of gastrointestinal bleeding

Medical Cause	Surgical Cause
<p>Bleeding peptic ulcer</p> <ul style="list-style-type: none"> start H2 receptor antagonist (e.g. cimetidine or ranitidine) if biopsy shows presence of <i>Helicobacter pylori</i> infection, treat accordingly. stop all incriminating drugs e.g. aspirin, steroids and anticoagulant drugs, if possible <p>Bleeding oesophageal varices ulcer</p> <ul style="list-style-type: none"> do not transfuse blood too rapidly as this will lead to increase in CVP and a rapid increase in portal pressure will precipitate further bleeding. refer paediatric surgeon and paediatric gastroenterologist to consider use of octreotide. <p>Pseudomembranous colitis</p> <ul style="list-style-type: none"> stop all antibiotics start oral metronidazole or oral vancomycin immediately. 	<p>When surgical cause is suspected, early referral to the surgeon is important so that a team approach to the problem can be adopted.</p> <ul style="list-style-type: none"> intussusception requires immediate surgical referral and intervention. Meckel's diverticulum malrotation